



PATIENT

Rickey MacDonald

SPECIES

Canine

BREED

Doodle

SEX

MN

AGE

4 y

WEIGHT

34 kg

PRESENTING CLINICAL SIGNS

HW positive since 11/20/25. Microfilaria negative. Vomiting daily for the past 4 days, lethargic.

ECHOCARDIOGRAPHIC FINDINGS

2D, M-mode, and Doppler study.

Left atrial size is normal. The mitral valve leaflets are mildly thickened, and a mild jet of mitral regurgitation is present. Left ventricular dimensions are normal. Left ventricular systolic function is normal. The aorta and aortic valve are normal. Right atrial and right ventricular dimensions are normal. The tricuspid valve leaflets are mildly thickened, and a mild jet of tricuspid regurgitation is present. The pulmonary artery and pulmonic valve are normal. No shunting lesions are visualized. No heartworms are visualized. No pericardial effusion or cardiac masses are seen.

LA - 39.8 mm
LVIDd - 39.1 mm
LVIDs - 27.8 mm
FS - 28.9%
RA - 24.1 mm
LVOT - 1.38 m/s
RVOT - 0.69 m/s
TR - 2.70 m/s

ASSESSMENT/RECOMMENDATIONS

Degenerative mitral and tricuspid valve disease - stage B1

This examination demonstrates mild regurgitation of blood across Rickey's mitral and tricuspid valves resulting from degenerative valve disease. The hemodynamic effects of the regurgitations also appear to be mild, as Rickey does not have secondary dilation of any of his cardiac chambers, and his ventricular systolic function is normal. As such, Rickey's current risk for the development of clinical signs secondary to his valvular diseases, such as coughing, exercise intolerance, syncope, labored breathing, and abdominal distension, appears to be low.

No heartworms are seen in this exam, suggesting that Rickey's worm burden is relatively low and that his heartworm disease is not the cause of his recent vomiting and lethargy.

Confirmation of Rickey's heartworm positive status using a different company's antigen test is recommended. Should this test be positive, I recommend treating Rickey on doxycycline (10 mg/kg BID) for 4 weeks. One month after the doxycycline is completed, heartworm adulticide therapy (3-dose protocol) may commence. Strict exercise restriction is recommended throughout the course of therapy, and tapering doses of prednisone can be given with each injection to reduce Rickey's risk for pulmonary embolism.

No therapy is recommended at this stage of Rickey's valvular diseases.

A recheck echocardiogram is recommended in 6 months. A recheck heartworm antigen test is recommended 9 months after the final melarsomine injection.

INTERPRETED BY

Keith Blass, DVM, MS,
DACVIM (Cardiology)

IMAGING PERFORMED BY

Amanda Stewart

HOSPITAL NAME

Headon Forest

REFERRING VET

Dr. S

INVOICE

DATE

12/5/25



PATIENT

Rickey MacDonald

SPECIES

Canine

BREED

Doodle

SEX

MN

AGE

4 y

WEIGHT

34 kg

INTERPRETED BY

Keith Blass, DVM, MS,
DACVIM (Cardiology)

IMAGING PERFORMED BY

Amanda Stewart

HOSPITAL NAME

Headon Forest

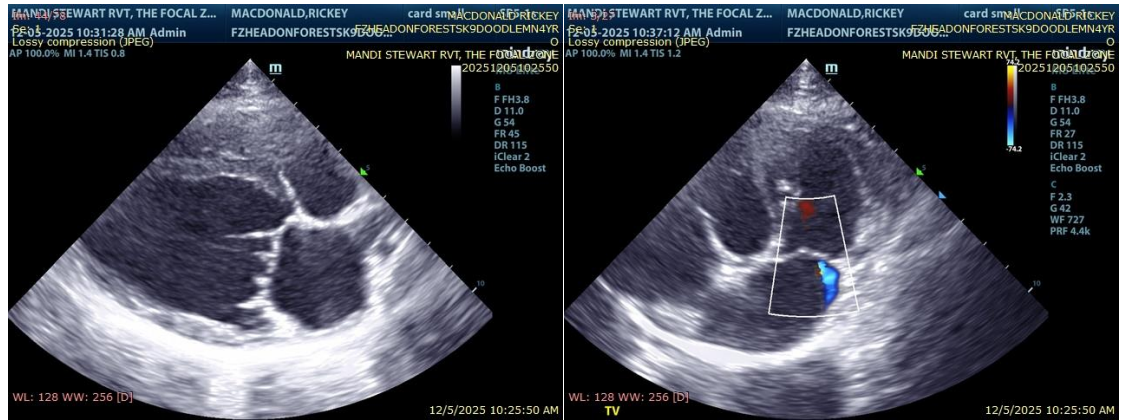
REFERRING VET

Dr. S

INVOICE

DATE

12/5/25



The information and recommendations provided are based on the images presented by the referring veterinarian/sonographer. No evaluation can be communicated regarding pathology that was not visible in the image/video clips provided.

Thank you for this referral. If the clinical or image interpretation does not parallel your findings or if I can be of any further assistance please contact me.

Keith Blass, DVM, MS, DACVIM (Cardiology)

info@SonoPath.com